ICRS International Cartilage Repair Society
ELECTRONIC POSTER
ICRS 2010 | September 26-29 | Sitges/Barcelona
Geistlich Surgery

The clinical safety and utility of an osteoconductive, bioabsorbable, scaffold for the use in treatment of full thickness chondral and osteochondral defects of the distal femur

e-Poster: P325

Congress: ICRS 2010

Type: Electronic Poster

Topic: Clinical Research / Scaffolds

Authors: R.C. Lehman[1], P.A. Davidson[2]; [1]Kirkwood, MO/US, [2]Park City, UT/US

MeSH:

Cartilage, Articular [A02.165.407.150]

Keywords: Knee, Cartilage, Osteochondral, Scaffold

Any information contained in this pdf file is automatically generated from digital material submitted to e-Poster by third parties in the form of scientific presentations. References to any names, marks, products, or services of third parties or hypertext links to third-party sites or information are provided solely as a convenience to you and do not in any way constitute or imply ICRS's endorsement, sponsorship or recommendation of the third party, information, product, or service. ICRS is not responsible for the content of these pages and does not make any representations regarding the content or accuracy of material in this file.
As per copyright regulations, any unauthorised use of the material or parts thereof as well as commercial reproduction or multiple distribution by any traditional or electronically based reproduction/publication method is strictly prohibited.
You agree to defend, indemnify, and hold ICRS harmless from and against any and all claims, damages, costs, and expenses, including attorneys' fees, arising from or related to your use of these pages.
Please note: Links to movies, ppt slideshows and any other multimedia files are not available in the pdf version of presentations.
www.cartilage.org

1. Abstract

Introduction: This report describes the clinical safety and utility of an osteoconductive, bioabsorbable, scaffold consisting of β-TCP, PLA and Type I collagen for the use in treatment of full thickness chondral and osteochondral defects (< 2cm^2) of the distal femur.

Materials and Methods: Patients enrolled in the study received 1 or 2 OsseoFit™ Porous Tissue Matrix™ implants on the femoral condyles (MFC or LFC) or trochlea. The study received IRB approval. Study endpoints are rate of complications related to the implant, change in KOOS scores and MRI findings with the MOCART Scale. The study was retrospective, conducted at a single center. MRI at approximately 6, 18 and 36 months post-operatively.

Demographics: 22 subjects with a mean age 37.7 ± 11.2 years were enrolled. 16 subjects received 1 implant and 6 subjects received 2 implants. Cartilage lesions were 1.2 ± 0.6 cm^2(0.64–2.64). 28 OsseoFit devices were implanted as follows: MFC=14, LFC=7 and trochlea=7. Concurrent surgical procedures included: meniscectomy in 13 subjects, ACL reconstruction in 6 subjects, debridement of other chondral surfaces in 16 subjects and other cartilage reparative techniques (e.g. microfracture, OAT, etc.) in 4 subjects.

Results: At an average follow-up of 17.3 ± 4.5 months, post-operative KOOS Pain and ADL subscale scores increased by 33.8 ± 24.9 points ($p<0.001$) and 34.8 ± 25.3 points ($p<0.001$), respectively. There was no evidence of implant failure, implant delamination, hypertrophy, osseous necrosis, or significant reactive marrow edema. MRI evaluation was performed at 159 ± 80.5 days post-operative. Complete defect filling was seen in 19/28 implants. Complete integration to the surrounding cartilage was seen in 27/28 implants. Complications associated with the knee surgeries were minimal.

Conclusion: At early follow-up, the OsseoFit™ device appears to be safe and contributed to improved clinical outcomes in the treatment of full thickness cartilage lesions (< 2cm^2) of the knee.

2. Purpose

The purpose of this study was to evaluate the clinical safety and utility of the OsseoFit™ Porous Tissue Matrix™ implant for the treatment of full thickness chondral and osteochondral defects of the distal femur. This is believed to be the first report on the use of this implant in an osteochondral application.

3. Methods and Materials

OsseoFit (TM) Device Description



Device Description: The OsseoFit™ Porous Tissue Matrix™implant is a highly porous, biphasic implant comprised of a Type I collagen component, and ceramic-polymer component of β-tricalcium phosphate suspended within a polylactic acid lattice. These are three well-characterized biomaterials with a long history of use in orthopedics. OsseoFit implants are available as cylinders in 4, 6, 8, 10, 12 or 15mm diameters.

Study Design: Retrospective, single-center, non-randomized study of patients who received an OsseoFit™ implant on the distal femur. The study was approved by the Western Institutional Review Board (Olympia, WA, USA).

Inclusion Criteria: Patients were eligible to participate if the following criteria was met:

- ≥16 years old
- ≤ 2 OsseoFit devices were implanted on the medial femoral condyle, lateral femoral condyle or trochlea
- Surgery was > 3 months prior to study initiation
- Post-operative MRI available for standardized evaluation
- Written informed consent was obtained

Exclusion Criteria: Patients were excluded from the study if any of the following criteria was present:

- Inflammatory arthropathy (i.e., rheumatoid arthritis, systemic lupus or active gout)
- Synovial proliferative disorder
- Osteomyelitis or other active infection
- Body mass index greater than 35
- Chemotherapy within the past 2 years

- Radiation therapy to the injured lower extremity within the past 2 years
- Patient was receiving workman's compensation for a knee injury that occurred > 12 months prior to surgery
- The patient was involved in active knee-related litigation

Endpoints:

- Change in the Knee Injury and Osteoarthritis Outcome Score ("KOOS")
- Rate of complications related to the OsseoFit implant
- Cartilage Defect Filling on MRI
- Integration to the surrounding native cartilage on MRI

4. Results

15mm OsseoFit (TM) Implant in situ

Demographics

# of Patients	22
Age (years)	37.7 ± 11.2
Male gender	12
BMI	26.5 ± 4.1
Symptoms > 12 months	7
History of OA	6
Prior viscosupplementation	5
Prior ACL reconstruction	3
Prior meniscectomy/meniscus repair	4
Prior chondral surface repair	6

Surgical Procedure

Cartilage Lesion Location	
MFC	14
LFC	7
Trochlea	7
Lesion size (cm2)	1.2 ± 0.6
# of OsseoFit™ implants	28
Patients with 1 implant	16
Patients with 2 implants	6
Concurrent surgical procedures	
Meniscectomy	13
ACL reconstruction	6
Concurrent chondral surface repair	
Debridement	16
Microfracture	2
OAT	1
Subchondral Drilling	1

KOOS Subscale Scores:

	Pain	Symptoms	ADL	Sports & Rec.	QOL
Pre-Op	47.9 ± 21.1	45.3 ± 19.6	52.2 ± 21.7	20.0 ± 27.0	18.8 ± 21.8
17.3 ± 4.5 months post-op	81.7 ± 14.6	75.4 ± 16.4	85.5 ± 15.5	61.3 ± 27.7	60.6 ± 24.9
Change	+33.8 ± 24.9 p < 0.001	+30.1 ± 26.6 p < 0.001	+34.8 ± 25.3 p < 0.001	+41.4 ± 31.1 p < 0.001	+41.8 ± 29.4 p < 0.001

MRI Evaluation

Time from Surgery to MRI (months)	5.4 ± 2.7
Degree of defect repair and filling	
Complete	67.9%
Hypertrophy	0.0%
> 50% filling	10.7%
< 50% filling	14.3%
Subchondral bone exposed	0.0%
Integration to border zone	
Complete	96.4%
Incomplete: Demarcating border visible	3.6%
Incomplete: > 50%	0.0%
Incomplete: < 50%	0.0%

Surface of repair tissue	
Intact	64.3%
Damaged < 50	28.6%
Damaged > 50%	7.1%
Signal intensity of repair cartilage (T2- Weighted)	
Isointense	64.3%
Hypointense	21.4%
Moderately hyperintense	14.3%
Markedly hyperintense	0.0%

Implant-related Complications

Implant failure	0.0%
Implant delamination	0.0%
Implant migration	0.0%
Implant removal	4.5%*
Bony hypertrophy	0.0%
Necrosis	0.0%
Osteomyelitis	0.0%

*OsseoFit™ implant was removed due to unrelieved knee pain. Unicompartmental arthroplasty

performed.

5. Conclusions

At early follow-up, the OsseoFit™ implant appears to be safe and contributed to improved clinical outcomes in the treatment of full thickness cartilage lesions (< 2cm^2) of the knee.

6. References

No References

7. Author Information

Richard C. Lehman, MD

333 S Kirkwood Road, Suite 200

St. Louis, MO 63122

USA

(314) 909-1666

rclehman123@gmail.com

Philip A. Davidson, MD

2200 Park Avenue, Building D

Park City, UT 84060

USA

(435)615-8822

phildavidsonmd@gmail.com

8. Mediafiles

15mm OsseoFit (TM) Implant in situ

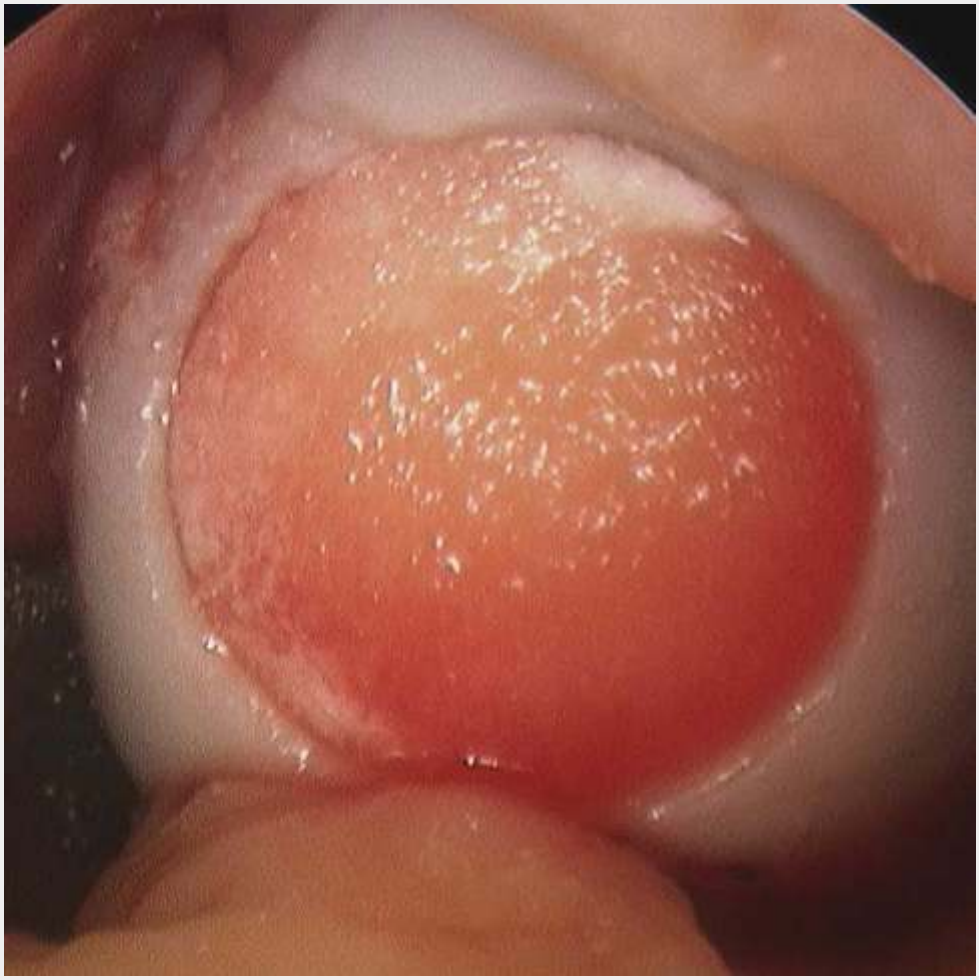

OsseoFit (TM) Device Description